

## Digital Artery Perforator Flaps for Fingertip Reconstructions

Isao Koshima, M.D.  
Katsuyuki Urushibara, M.D.  
Norio Fukuda, M.D.  
Masayuki Ohkochi, M.D.  
Takashi Nagase, M.D.  
Koichi Gonda, M.D.  
Hiroataka Asato, M.D.  
Kotaro Yoshimura, M.D.  
*Tokyo and Okayama, Japan*

**R**egarding reconstructive methods for fingertip, local homodigital advancement flaps including V-Y closure from ipsilateral or bilateral sides of the finger and volar advancement flaps<sup>1-4</sup> have been popular. Although these methods are very convenient, the major disadvantages are limited length of advancement and limited size of flaps. Cross-finger flaps<sup>5,6</sup> and thenar flaps<sup>6-9</sup> require a second-stage operation. Other methods for repairing fingertip defects are normograde neurovascular island flaps<sup>10-13</sup> and reverse-flow homodigital artery flaps,<sup>14-18</sup> which require dissection or transection of the digital artery, sometimes longer and deeper dissection for the neurovascular bundle, and often skin grafting for donor defects. The free hemipulp flap, venous flap,<sup>19,20</sup> medial plantar perforator flap, and trimmed toe tip method<sup>21,22</sup> also require special microsurgical techniques.

To overcome these disadvantages, in this article, we describe a new method for resurfacing the fingertip: the digital artery perforator flap with smaller perforators (arterioles and venules) arising from the digital artery. This flap seems to be less invasive, reliable, and technically easy for fingertip reconstructions.

*From the Departments of Plastic and Reconstructive Surgery, Graduate School of Medicine, University of Tokyo, and Kawasaki Medical School.*

*Received for publication February 3, 2005; accepted January 10, 2006.*

*The first two authors contributed equally to this work.*

*Presented in part at the Third International Course on Perforator Flap, in Munich, Germany, November 12, 1999, and at the American Society for Reconstructive Microsurgery Symposium, "Perforator Flaps," in San Diego, California, January of 2001.*

*Copyright ©2006 by the American Society of Plastic Surgeons*

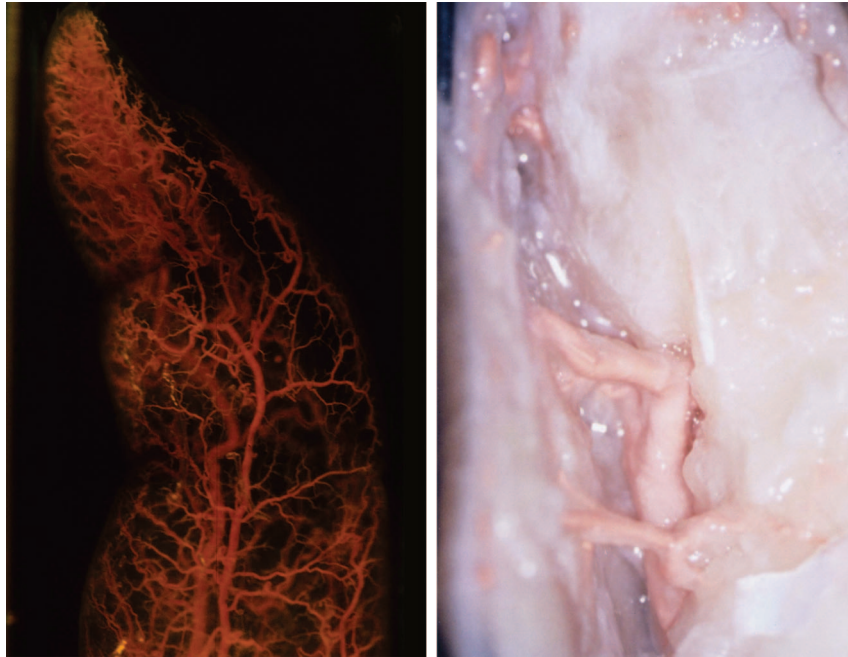
DOI: 10.1097/01.prs.0000232987.54881.a7

### PATIENTS AND METHODS

#### Anatomy and Flap Elevations

Arterial embalming techniques using three cadaver fingers were used to observe digital artery perforators and their terminal arterioles into the subdermal layers. Thereafter, dissections were carried out through the digital artery and its perforator systems to detect the three-dimensional distribution within subcutaneous tissue in the distal phalanx. There are many branches from the digital arteries in the lateral aspect of the fingers. These branches perforate the thin fascia and adiposal tissue and terminate multiple arterioles into the subdermal layer; therefore, we named them digital artery perforators rather than branches. Rich perforating arterioles and venules between these perforators exist in the subcutaneous tissue through the midlateral line of the fingers. Regarding the drainage system, the digital artery usually has no concomitant vein but sometimes has double or single concomitant veins. The drainage venules connect to the dorsal and volar cutaneous venous systems in the subcutaneous tissue. The nervous system also has rich vascular networks (arterioles and venules) and links to the subcutaneous vascular network systems (Fig. 1).

The design of the digital artery perforator flap is outlined on the lateral or medial aspect of the fingers because these areas can be easily closed after flap elevation. Under a digital block, an incision is made through the flap outline and the flap is elevated above the digital neurovascular bundle. Some other perforators and subdermal venules far from the base of the flap are coagulated and transected. At the proximal side of the flap near the defect, only the distal perforator arising from the digital artery is preserved as a pedicle vessel. If there are no dominant perforators at the flap base, adiposal tissue should be

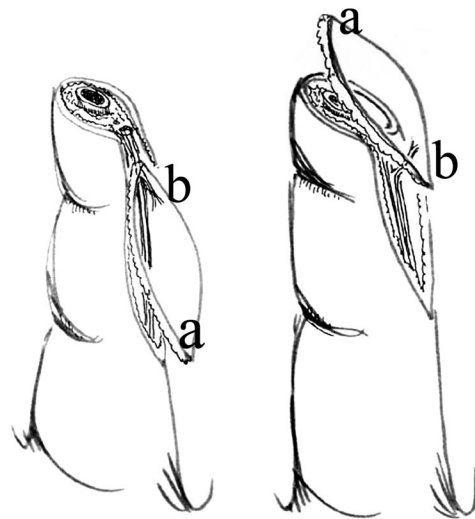


**Fig. 1.** Three-dimensional distribution of the digital artery perforators (arterial embalming method using a cadaver finger). Many perforators arise from the digital artery and terminate in the multiple arteriolar system in the subdermal layer. One terminal arteriole can be a pedicle of this flap.

preserved at the flap base, because the subcutaneous tissue often contains superficial arterioles and it could nourish the flap. Then, the island flap with a perforator is rotated 180 degrees to cover the defect. The flap pedicle includes the digital artery perforator and the subcutaneous venular system within a small amount of adiposal tissue. This flap need not include large vessels such as subcutaneous venous system, reverse-flow (or normograde) digital arteries, or the transverse palmar arch of the digital artery<sup>13</sup> (Fig. 2).

### Patient Summary

From October of 1998 to December of 2004, a total of five patients underwent repair with digital artery perforator flaps. The age of the patients ranged from 24 to 48 years, and there were four men and one woman. Four cases were established uncured finger defects, and one was a fresh fingertip defect. All flaps survived. The size of the flaps ranged from  $2 \times 0.7$  cm to  $4 \times 2$  cm. Regarding the postoperative sensory recovery of the digital artery perforator flap, the patient in case 4 showed a Semmes-Weinstein test value of 3.61 (that of the normal left middle finger was 2.83) at 7 months after surgery. No patients had postoperative hypersensitivity of the repaired fingertips or cold intolerance (Table 1).



**Fig. 2.** Schematic drawing of the digital artery perforator flap. The pedicle of this flap is the distal perforator of the digital artery (a and b, bilateral edges of the flap).

## CASE REPORTS

### Case 2

A 48-year-old woman had crush amputation of her left fingers caused by a press machine, and the amputated fingers could not be replanted. Nine weeks after the injury, the exposed proximal phalangeal bone of the thumb was covered with a digital artery perforator flap. After resection of the exposed proximal phalangeal bone tip, an island digital artery perfora-

**Table 1. Patient Summary\***

Patient	Age (yr)	Sex	Defect	Flap Size (cm)	Semmes-Weinstein Test
1	47	Male	Right little finger	2.5 × 1.0	7 mo after surgery: 3.61 (2.83/normal)
2	48	Female	Left thumb	4 × 2	
3	24	Male	Left middle finger	2 × 0.7	
4	43	Male	Right middle finger	3.5 × 2	
5	39	Male	Left little finger	2.5 × 1.0	

\*None of the patients experienced complications.

tor flap, 4 × 2 cm, was transferred from the lateral aspect of the thumb to cover the prepared defect. Three cutaneous veins were ligated at the margin of the flap. The donor defect for the flap was closed with a medial plantar split-thickness skin graft without tie-over. Postoperatively, the flap was pink, not congestive, and survived completely (Fig. 3).

### Case 3

A 24-year-old man had double amputations at the distal interphalangeal and middle phalanx of his left middle finger. The finger was replanted successfully with a vein graft under digital block. Regardless of active rehabilitation, however, postoperative flexion contracture at the distal interphalangeal joint of the finger caused him difficulty with his daily work. Therefore, 5 months after replantation, secondary repair including distal interphalangeal joint union and release of scar contracture on the volar side of the finger was carried out under digital block. The resulting volar defect was covered with an island digital artery perforator flap, 20 × 7 mm, from the lateral aspect of the finger. The donor defect was closed directly. Postoperatively, the color of the flap was excellent. The flap survived completely (Figs. 4 and 5).

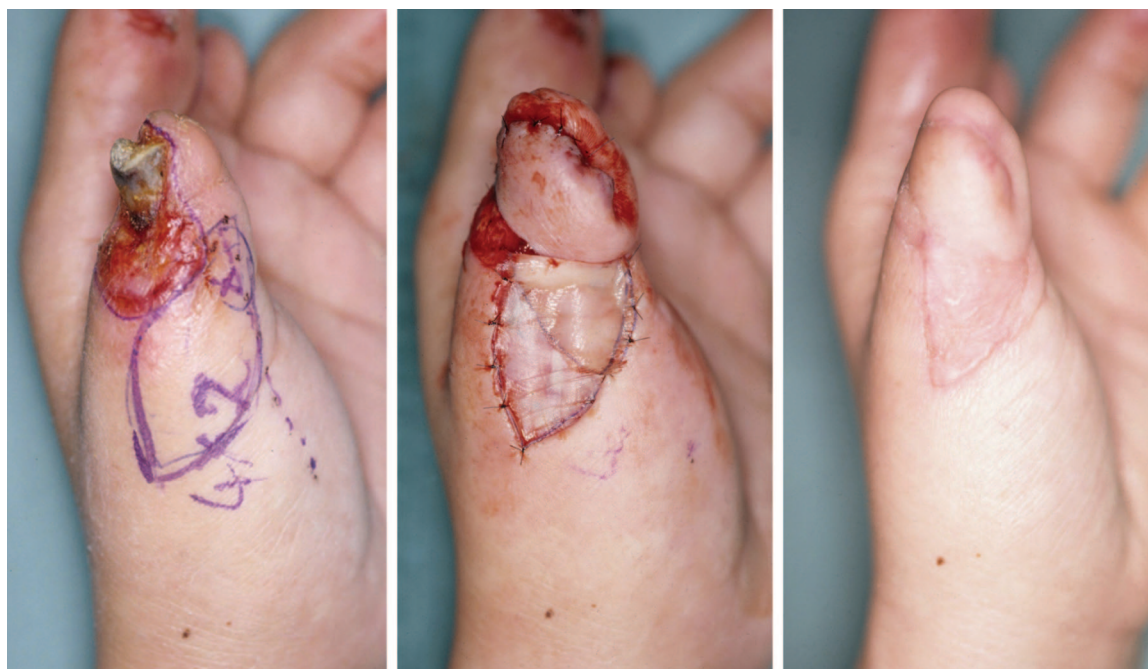### Case 4

A 43-year-old man sustained fingertip crush amputation of the right middle finger caused by a press machine. Replantation

was impossible because the crushed distal segment had no arterioles or venules. The exposed distal phalangeal bone tip was not trimmed and an island digital artery perforator flap from the lateral aspect of the finger was elevated to cover the defect under digital block. The donor site was closed directly. The flap survived postoperatively, and 2 months later the patient could return to his original job. The digital artery perforator flap showed a Semmes-Weinstein test value of 3.61 (that of the normal contralateral left middle finger was 2.83) at 7 months after surgery (Figs. 6 through 8).

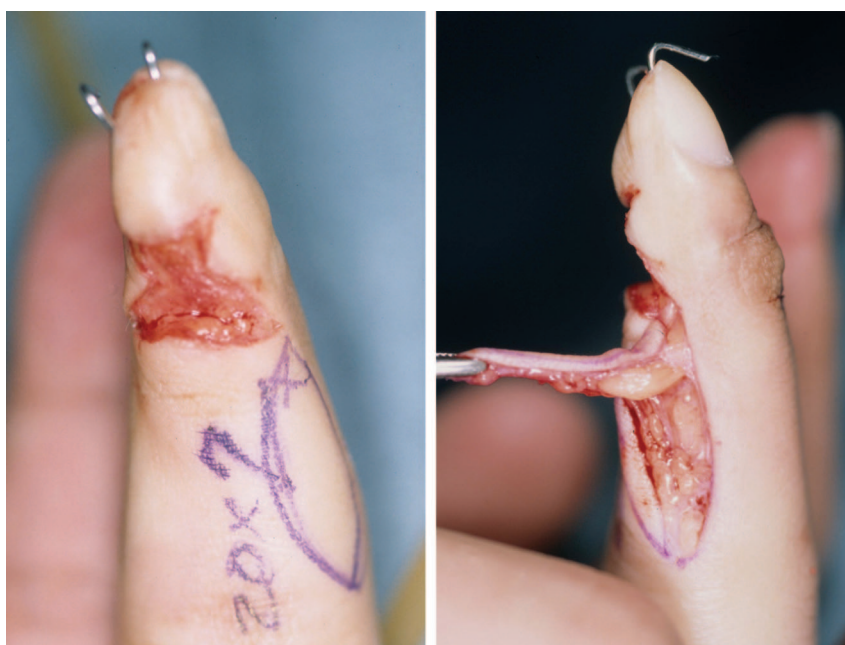## DISCUSSION

Regarding reconstructive methods for fingertips, local homodigital advancement flaps, cross-finger flaps and thenar flaps, local island flaps, reverse flow homodigital artery flaps, and microsurgical free flaps (e.g., the hemipulp flap, venous flap, medial plantar perforator flap, and trimmed toe tips) have been popularized. In this article, we described a new method for resurfacing the fingertip: digital artery perforator flaps using a smaller perforator (arteriole and venule) arising

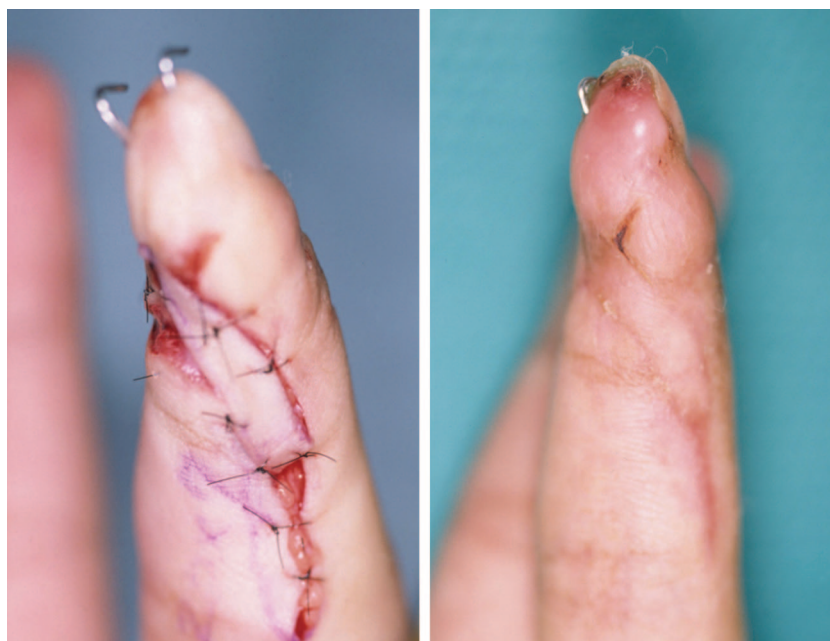

**Fig. 3.** The patient in case 2. (Left) Crushed amputation of the thumb caused by a press machine. (Center) Nine weeks later, exposed bone was resected and covered with a digital artery perforator flap. (Right) Three months after surgery.





**Fig. 4.** The patient in case 3. (Left) Defect after release of the scar contracture of the left middle finger. (Right) Digital artery perforator flap harvested from the lateral aspect without transection of the digital artery.

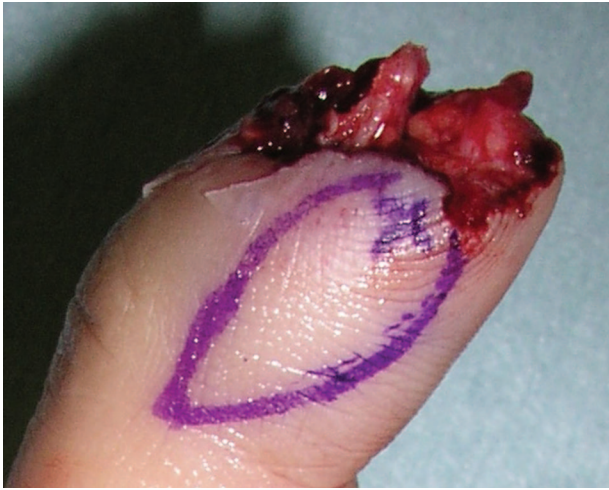

**Fig. 5.** The patient in case 3. (Left) Transferred digital artery perforator flap. (Right) Two months later.

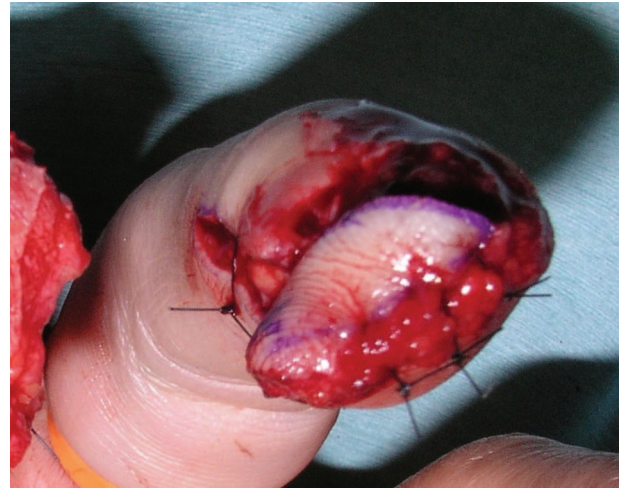
from the digital artery and concomitant vein (or subdermal vein). This flap is elevated from the lateral portion of the fingers, the pedicle perforators are at the adjacent midlateral pulp of the tip defect, and a flap is transposed with 180 degrees

of rotation. This flap can be easily elevated under digital block and tourniquet.

Among methods previously used, the reverse-flow homodigital artery flap is popular and has a design similar to this digital artery perforator flap.



**Fig. 6.** The patient in case 4. Crushed amputation of the right middle finger was covered with a digital artery perforator flap.

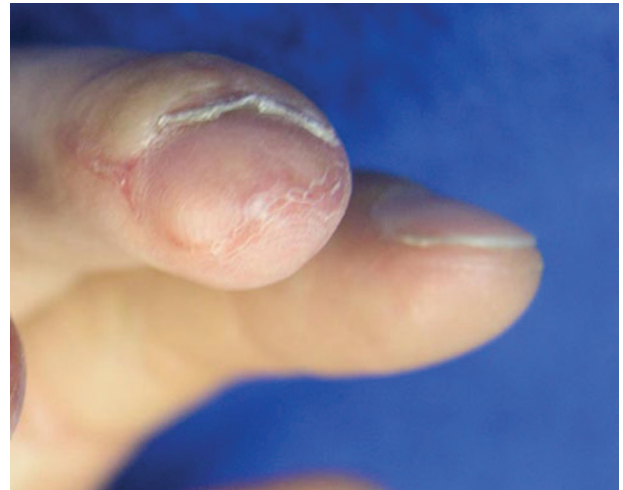

**Fig. 7.** The patient in case 4. The transferred digital artery perforator flap.

However, the reverse-flow flap requires transection at the proximal level of the digital artery and the flap is elevated more distant from tip defects (the proximal phalanx). These are the disadvantages of the reverse flap. The digital artery perforator flap with normograde flow does not require digital artery transection and is elevated from an area close to tip defects. In addition, Kim's volar flap based on the transverse branch of the digital artery<sup>13</sup> seems to be an excellent method, because there is no transection of the digital artery or 180 degrees of rotation. However, this flap requires a skin graft on the volar donor defect, which may cause flexion contracture. The digital artery perforator flap may require smaller arterioles instead of a branch (main perforator) of the digital artery, and the donor is lateral pulp with loose tension and results in little postoperative scar contracture.

Regarding the territory of the digital artery perforator flap, two vascular systems can be selected as the candidate pedicle for this flap. One is the main perforator arising from the digital artery that nourishes a wide, large flap, as in the patient in case 2 (4 × 2 cm). The other is the superficial arteriolar system, which is the terminal region of the perforator. This is a suitable pedicle for flaps covering incurable defects surrounded by scarred skin. This pedicle can survive as a small flap and is suitable for defects with a subcutaneous scar because dissection to the deeper main perforator is difficult.

Postoperative sensory recovery is good and depends on the severity of damage to the digital nerve. Crush injuries do not recover to a normal level. With simple clean-cut amputations, nearly



**Fig. 8.** The patient in case 4. Ten weeks after surgery.

normal return would be expected; no patients showed postoperative hypersensitivity of the repaired fingertips or cold intolerance.

The advantages of this method are as follows: no need for neurovascular bundle dissection or transection, suitable for emergency operation, reliable flap circulation, less invasive surgery, donor defect on lateral pulp can often be closed directly, short operative time, and no postoperative tenderness on the tip with this thick flap. The disadvantages include the fact that detection of the perforators requires loupe magnification.

Indications for this flap include all cases with fingertip injuries in emergency surgery, especially for patients with difficult arterial anastomoses without arteries in amputated segments; workers who require earlier return to work after injury;

and temporary coverage for young female patients and children, because other methods such as trimmed great or second toe tip transfers including nailplasty<sup>21,22</sup> seem to be more suitable from the cosmetic point of view.

A contraindication of this flap is the need for a larger flap that requires skin grafting, including the volar aspect of the donor defect. The graft may compress the digital nerve and result in postoperative pain syndrome.

**Isao Koshima, M.D.**

Department of Plastic and Reconstructive Surgery  
Graduate School of Medicine  
University of Tokyo  
7-3-1, Hongo, Bunkyo-ku  
Tokyo 113-8655, Japan  
koushimai-pla@h.u-tokyo.ac.jp

## REFERENCES

1. Kutler, W. A method for repair of finger amputation. *Ohio State Med. J.* 40: 126, 1944.
2. Atasoy, E., Ioakimid, E., Kasdan, M. L., et al. Reconstruction of the amputated finger tip with a triangular volar flap. *J. Bone Joint Surg. (Am.)* 52: 921, 1970.
3. Evance, D. M., and Martin, D. L. Step-advancement island flap for finger-tip reconstruction. *Br. J. Plast. Surg.* 41: 105, 1988.
4. Venkataswami, R., and Subramanian, N. Oblique triangular flap: A new method of repair for oblique amputations of the finger tip and thumb. *Plast. Reconstr. Surg.* 66: 296, 1980.
5. Tempest, M. N. Cross finger flaps in the treatments of injuries to the finger tip. *Plast. Reconstr. Surg.* 7: 205, 1952.
6. Smith, J. R., and Bom, A. F. An evaluation of finger-tip reconstruction by cross-finger and palmar pedicle flap. *Plast. Reconstr. Surg.* 35: 409, 1965.
7. Beasley, R. W. Reconstruction of amputated finger tips. *Plast. Reconstr. Surg.* 44: 349, 1969.
8. Miller, A. J. Single fingertip injuries treated by thenar flap. *Hand* 6: 311, 1974.
9. Melone, C. P., Beasley, R. W., and Carotens, J. H. The thenar flap: An analysis of its use in 150 cases. *J. Hand Surg. (Am.)* 7: 291, 1982.
10. O'Brien, B. Neurovascular island pedicle flaps for terminal amputations and digital scars. *Br. J. Plast. Surg.* 21: 258, 1968.
11. Macht, S. D., and Watson, K. H. The Moberg volar advancement flap for digital reconstruction. *J. Hand Surg. (Am.)* 5: 372, 1980.
12. Chen, C. T., and Wei, F. C. Lateral-dorsal neurovascular island flaps for pulp reconstruction. *Ann. Plast. Surg.* 45: 616, 2000.
13. Kim, K. S., Yoo, S. I., Kim, D. Y., Lee, S. Y., and Cho, B. H. Fingertip reconstruction using a volar flap based on the transverse palmar branch of the digital artery. *Ann. Plast. Surg.* 47: 263, 2001.
14. Weeks, P. M. Local arterialized flap coverage of difficult hand defects preserving donor digit sensibility (Discussion). *Plast. Reconstr. Surg.* 72: 858, 1983.
15. Lai, C. S., Lin, S. D., and Yang, C. C. The reverse digital artery flap for finger tip reconstruction. *Ann. Plast. Surg.* 22: 495, 1989.
16. Kojima, T., Tsuchida, Y., Hirase, Y., and Endo, T. Reverse vascular pedicle digital island flap. *Br. J. Plast. Surg.* 43: 290, 1990.
17. Del Bene, M., Petrolati, M., Raimondi, P., Tremolada, C., and Muset, A. Reverse dorsal digital island flap. *Plast. Reconstr. Surg.* 93: 552, 1994.
18. Niranjana, N. S., and Armstrong, J. R. Homodigital reverse pedicle island flap in soft tissue reconstruction of the finger and the thumb. *J. Hand Surg. (Br.)* 19: 135, 1994.
19. Yoshimura, M., Shimada, T., Imura, S., Shimamura, K., and Yamauchi, S. The venous skin graft method for repairing skin defects of the fingers. *Plast. Reconstr. Surg.* 79: 243, 1987.
20. Kayikcioglu, A., Akyurek, M., Safac, T., Ozkan, O., and Kecik, A. Arterialized venous dorsal digital island flap for fingertip reconstruction. *Plast. Reconstr. Surg.* 102: 2368, 1998.
21. Koshima, I. Distal thumb reconstruction with a great toe partial-nail preserving transfer technique (Discussion). *Plast. Reconstr. Surg.* 101: 120, 1998.
22. Koshima, I., Inagawa, K., Urushibara, K., Okumoto, K., and Moriguchi, T. Fingertip reconstruction using partial-toe transfers. *Plast. Reconstr. Surg.* 105: 1666, 2000.