

Experience with a Strong Bleaching Treatment for Skin Hyperpigmentation in Orientals

Kotaro Yoshimura, M.D., Kiyonori Harii, M.D., Takao Aoyama, Ph.D., and Tatsuji Iga, Ph.D.

Tokyo, Japan

Although a variety of topical treatments have been used for skin hyperpigmentation, the effectiveness of each varies after prolonged treatment. In this study, 136 Oriental patients who were followed up for more than 12 weeks were analyzed. The treatment protocol was composed of two steps: bleaching (2 to 6 weeks) and healing (2 to 6 weeks); 0.1% to 0.4% all-trans retinoic acid aqueous gel was originally prepared and applied concomitantly with hydroquinone-lactic acid ointment for bleaching. After obtaining sufficient improvement of the hyperpigmentation, a corticosteroid was applied topically with hydroquinone and ascorbic acid for healing. Improvement was evaluated with a narrow-band reflectance spectrophotometer. The results were successful in more than 80 percent of cases of senile lentigines and postinflammatory hyperpigmentations, especially on the face. Sixty percent of cases of nevus spilus were also successfully treated. Although the transient adverse effects of this treatment may be more severe than conventional treatment, this strong bleaching protocol improves a variety of hyperpigmented lesions, including nevus spilus, with a higher success rate and a shorter treatment period than conventional protocols. (*Plast. Reconstr. Surg.* 105: 1097, 2000.)

All-trans retinoic acid (atRA; tretinoin) has been used topically for the treatment of acne, photodamaged skin, and hyperpigmentation and before and after skin resurfacing procedures, such as carbon dioxide laser treatment and chemical peeling.¹⁻⁵ Kligman and Willis⁶ well-known regimen and several modifications to it^{7,8} have been widely used topical bleaching formulas for two decades, and a number of products based on them are commercially available. However, patient improvement with these treatments is variable and sometimes limited or unrecognizable, and it usually takes a prolonged course of treatment.

We proposed a new bleaching protocol us-

ing an aqueous gel with a high concentration of atRA, and we have treated more than 300 Oriental patients who have hyperpigmented skin lesions, such as senile lentigines, postinflammatory hyperpigmentation, melasma, and nevus spilus, with it. These hyperpigmented skin lesions were previously treated with a variety of therapies, including laser and chemical peeling; except for senile lentigines, the results were not very satisfactory.⁹⁻¹² The management of postoperative hyperpigmentation is quite important for dermatologic or plastic surgeons performing facial skin resurfacing. Furthermore, no reports exist on the effectiveness of topical treatments for nevus spilus, for which no standard therapy exists to date.^{11,12} Although our protocol requires two steps (a bleaching step and a healing step) and transient adverse skin reactions associated with this treatment may be severe, it improves a variety of hyperpigmented lesions, including nevus spilus, with a higher success rate and a shorter treatment period than conventional protocols.

PATIENTS AND METHODS

Preparation of Ointments

AtRA aqueous gels (atRA gel) with three different concentrations (0.1%, 0.2%, and 0.4%) were prepared at the Department of Pharmacy at the University of Tokyo. The precise formula for 1000 g of 0.1% to 0.4% atRA aqueous gel was as follows: 1 to 4 g of atRA (Sigma Chemical, St. Louis, Mo.), 10 g of Carbopol 940 (Goodrich Chemical, Hounslow, U.K.), 20 g of polyoxyethylene oleyl ether

(Kao, Tokyo, Japan), 0.26 g of methyl *p*-hydroxybenzoate (Wako Pure Chemical Industries, Osaka, Japan), 0.14 g of propyl *p*-hydroxybenzoate (Wako Pure Chemical Industries), 6 ml of 10% sodium hydroxide aqueous solution, and 1000 g of purified water. An ointment including 5% hydroquinone and 7% lactic acid (HQ-LA) and one including 5% hydroquinone and 10% L-ascorbic acid (HQ-AA) were also prepared at the Department of Pharmacy at the University of Tokyo. Plastibase (petrolatum polyethylene ointment base, Taisho Pharmacology, Osaka, Japan) and hydrophilic ointment were used as the ointment bases of the HQ-LA and HQ-AA ointments, respectively. Because all ointments (atRA gel, HQ-LA ointment, and HQ-AA ointment) were pharmacologically unstable, fresh ointments were prepared at least once a month and stored in a dark, cool (4°C) place.

Patients

After receiving written, informed consent, each ointment was topically applied to more than 300 patients with hyperpigmented skin lesions. A total of 136 patients who had hyperpigmented lesions in which the relative melanin value was more than 30 and who were followed up for more than 12 weeks were analyzed in this study. All of them were Oriental: 128 were Japanese, three were Chinese, three were Korean, and two were Indian. Clinical diagnoses of hyperpigmented lesions were classified into four categories: senile lentiginos, melasma, postinflammatory hyperpigmentation, and nevus spilus, which included café au lait spots. Patients with postinflammatory hyperpigmentation with a duration less than 6 months were excluded from this study. The ages of the patients ranged from 4 to 88 years (44.6 ± 15.3 years), and 112 patients were female. Patient data are summarized in Table I. Some patients had hyperpigmented lesions on more than one part of the body, so the total number of cases is 146. The data were analyzed according to clinical diagnosis and site of skin lesion. We had 90 cases of senile lentiginos (face, 61; trunk, 3; upper extremities, 24; and lower extremities, 2), 10 cases of melasma (all on the face), 28 cases of postinflammatory hyperpigmentation (face, 11; trunk, 6; upper extremities, 7; and lower extremities, 4), and 18 cases of nevus spilus (face, 9; trunk, 5; upper extremities, 2; lower extremities, 2).

TABLE I
Patient Data

| | |
|---|------------------|
| No. of patients | 136 |
| Age (years) | 44.6 \pm 15.3 |
| Sex (male:female) | 24:112 |
| Clinical diagnosis (site of lesions: face/trunk/UE/LE, no. of cases) | |
| SL | 90 (61/3/24/2) |
| ML | 10 (10/0/0/0) |
| PIH | 28 (11/6/7/4) |
| NS | 18 (9/5/2/2) |
| Total no. of cases* | 146 (91/14/33/8) |

UE, upper extremity; LE, lower extremity; SL, senile lentiginos; ML, melasma; PIH, postinflammatory hyperpigmentation; NS, nevus spilus.

* Because some patients had skin lesions at more than one site, the total number of cases exceeds the number of patients.

Treatment Protocol

Our treatment protocol is composed of two steps, bleaching and healing. In the bleaching step, pigmentation is aggressively treated, and transient adverse skin effects, such as erythema and irritation, are usually observed. Once satisfactory improvement is obtained, the healing step is started to reduce the erythema and inflammation. In some cases, pretreatment was conducted before bleaching.

Pretreatment. The application of HQ-LA ointment (HQ-AA ointment in some cases) to the skin lesions twice daily for several weeks was recommended to those who wanted to start the bleaching treatment in several weeks for personal reasons. In the summer, every patient was advised to have only a pretreatment with HQ-LA ointment until September to avoid strong ultraviolet irradiation during the bleaching step. In the daytime, a broad-spectrum sunscreen cream was always concomitantly applied with the ointments throughout the treatment period.

Bleaching. AtRA gel and HQ-LA ointment were applied to the skin lesions twice a day. Initially, the concentration of atRA was determined according to the location of the skin lesions: 0.1% atRA gel was used for the face, 0.2% for the trunk or upper extremities, and 0.4% for the lower extremities. Patients were told to visit our hospital 1, 2, 4, 6, 8, 12, and 16 weeks after starting this treatment. When the appropriate skin reaction was not observed at 1 week, the concentration of atRA was changed (usually to a higher one). In most cases, it took 2 to 6 weeks to finish this step.

If satisfactory improvement (80 percent improvement of relative melanin value) was not obtained after 8 weeks of continual treatment

TABLE II
Treatment Results

| | Senile Lentigines | Melasma | Postinflammatory Hyperpigmentation | Nevus Spilus | Total | Success Rate* |
|-------------------|-------------------|--------------|---------------------------------------|--------------|-------------------|---------------|
| Face | 61 (23/35/3/0) | 10 (2/5/2/1) | 11 (5/6/0/0) | 9 (3/3/3/0) | 91 (33/49/8/1) | 90.1% |
| Trunk | 3 (0/2/1/0) | 0 (0/0/0/0) | 6 (2/3/1/0) | 5 (2/1/1/1) | 14 (4/6/3/1) | 71.4% |
| Upper extremities | 24 (4/10/8/2) | 0 (0/0/0/0) | 7 (1/4/1/1) | 2 (0/1/1/0) | 33 (5/15/10/3) | 60.1% |
| Lower extremities | 2 (0/0/1/1) | 0 (0/0/0/0) | 4 (2/1/1/0) | 2 (0/1/0/1) | 8 (2/2/2/2) | 50.0% |
| Total | 90 (27/47/13/3)† | 10 (2/5/2/1) | 28 (10/14/3/1) | 18 (5/6/5/2) | 146 (44/72/23/7)† | |
| Success rate* | 82.2% | 70.0% | 85.7% | 61.1% | 79.5% | |

Results are described in number of cases as total (excellent/good/fair/poor).

* Success rates were calculated as follows: (number of "excellent" and "good" cases)/(number of total cases).

† Because some patients had skin lesions on more than one part of the body, the numbers shown exceed the actual number of patients.

with atRA gel and HQ-LA ointment, the treatment was discontinued. In these cases, a second treatment was started after a 2- to 3-month interval. Throughout this interval, we recommended pretreatment with HQ-LA (or HQ-AA) ointment before the second treatment, which was the same protocol as the first treatment.

Healing. After sufficient improvement of the hyperpigmentation was obtained, the application of atRA gel and HQ-LA ointment was discontinued, and topical application of corticosteroids (ointment with 0.12% betamethasone valerate or 0.3% prednisolone butylacetate) and HQ-AA ointment (HQ-LA ointment in some cases) for as short a time as possible (usually 1 to 2 weeks) was started to reduce the reactive erythema and inflammation. After the erythema was reduced to some extent, the application of the corticosteroid ointment was discontinued, and only HQ-AA ointment was continuously applied. In cases in which erythema was not reduced after a few weeks of the application of corticosteroid and HQ-AA ointment, HQ-AA ointment was also discontinued for a few weeks. In cases in which the reactive erythema was not severe, this step was omitted.

Posttreatment maintenance. After the bleaching and healing steps were finished, continual application of HQ-LA or HQ-AA ointment for several months was advised for posttreatment maintenance in some patients, including all patients with nevus spilus. When clinical signs of pigmentation recurrence were observed in patients with nevus spilus, atRA gel was also used as maintenance or a second treatment was started.

Evaluation of Results

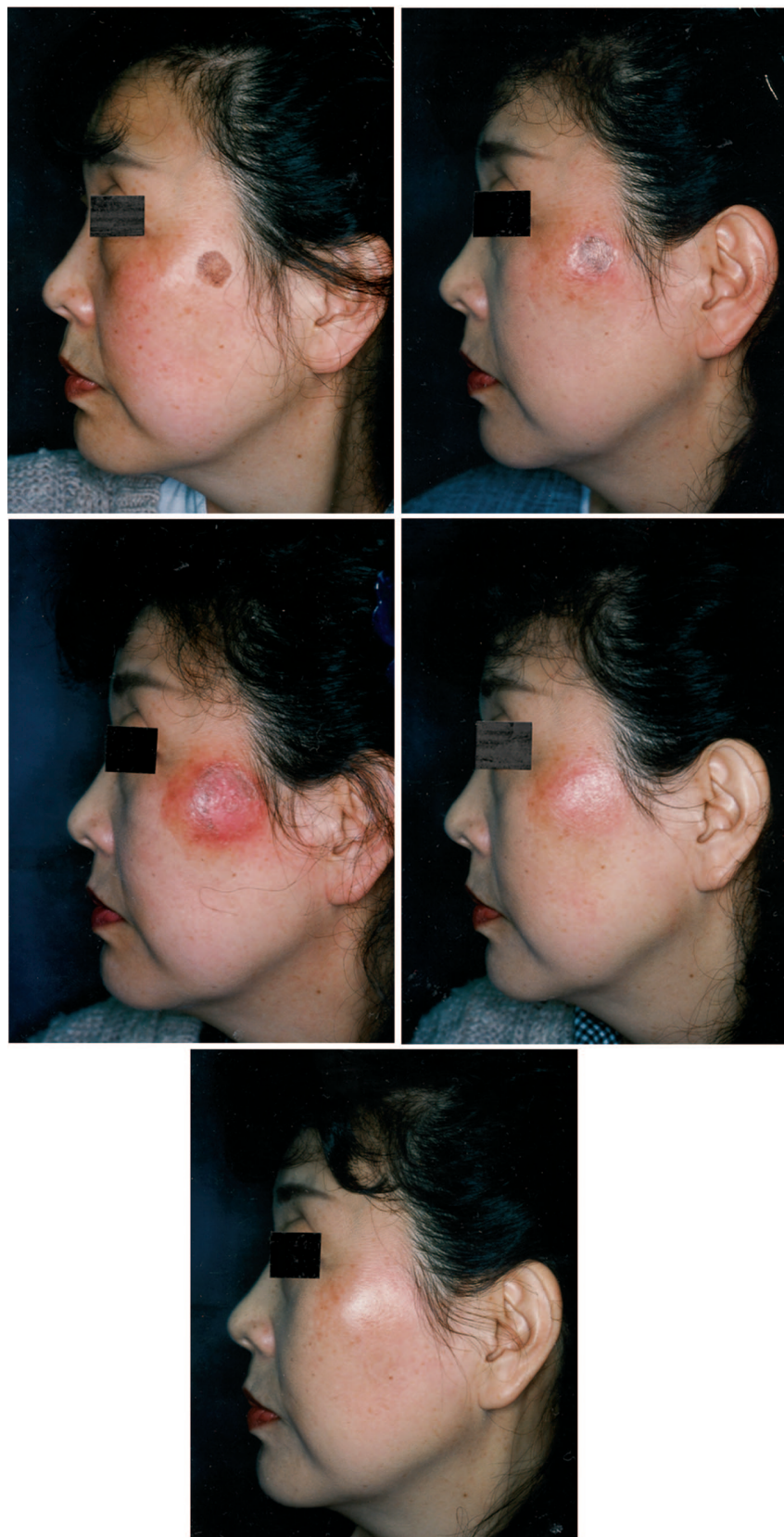Spectrophotometry. As an objective measurement of the color of the designated lesion and

the surrounding normal skin, a narrow-band reflectance spectrophotometer (Mexameter MX 16, COURAGE+KHAZAKA electric GmbH, Köln, Germany) was used at each clinical visit. The overall results were objectively evaluated by the melanin and hemoglobin values measured with the Mexameter.¹³ A measuring probe with a diameter of 5 mm emits light at three predefined wavelengths (568 nm, green; 660 nm, red; and 880 nm, infrared) and measures the light reflected by the skin. The melanin value was measured by using two wavelengths (660 and 880 nm) to achieve different absorption rates by the melanin granules. For the hemoglobin measurement, two wavelengths (568 nm and 660 nm) were also used. The melanin and hemoglobin values are calculated as follows:

$$\begin{aligned} \text{Melanin value} &= 500/\log 5 \\ &\times [(\log \text{infrared-reflection}/\text{red-reflection}) \\ &\quad + \log 5] \end{aligned}$$

$$\begin{aligned} \text{Hemoglobin value} &= 500/\log 5 \\ &\times [(\log \text{red-reflection}/\text{green-reflection}) \\ &\quad + \log 5] \end{aligned}$$

Each spot was measured three times, and the average of three measured values was calculated. The differences in the absolute melanin and hemoglobin values between a skin lesion and the surrounding normal skin are referred to in this article as the relative melanin value and the relative hemoglobin value of the skin lesion, respectively. These values indicate the intensity of pigmentation and erythema, respectively, relative to the surrounding normal skin. A negative melanin value means that the



measured spot is lighter than the control. Relative melanin values were compared before and after the first treatment, and the results were classified into the following four grades: excellent (final value ≤ 5), good (final value < 20 percent of value before treatment), fair (final value < 60 percent of that before treatment), and poor (final value ≥ 60 percent of that before treatment). The absolute melanin value of normal skin in Japanese persons and the relative melanin values of hyperpigmented lesions are usually 460 to 500 and 20 to 120, respectively. A relative melanin value of less than 5 is difficult to recognize clinically.

Statistics. The results were analyzed according to the diagnoses and locations of the skin lesions. Significant differences were sought using the Kruskal-Wallis test. Differences were considered significant when H values $> \chi^2$ (0.95).

RESULTS

In general, erythema was seen in a few days; this was followed by continuous scaling during the first week.¹⁴ Erythema and scaling were usually seen continuously throughout the bleaching step. Formation of a thin crust was also seen in some patients during the second week. After the thin crusts came off, the elimination of pigmentation was usually obtained. An improvement of hyperpigmentation was obtained after bleaching for 2 to 4 weeks in most cases of senile lentigines or postinflammatory hyperpigmentation, but a somewhat longer period was usually required for patients with nevus spilus. A second treatment was performed for further improvement in 19 cases (21.1 percent) with senile lentigines, six cases (60.0 percent) of melasma, one case (3.6 percent) of postinflammatory hyperpigmentation, and 16 cases (88.9 percent) of nevus spilus.

The results of the treatment were evaluated with spectrophotometry; they are summarized in Table II. Cases evaluated as excellent or good are referred to as successful in this article, and the success rates were calculated as follows: (number of excellent and good cases) / (number of total cases).

Of the senile lentigines cases, 27 (23 on the face and four on the upper extremities) were evaluated as excellent, 47 (35 on the face, two

on the trunk, and 10 on the upper extremities) as good, 13 (three on the face, one on the trunk, eight on the upper extremities, and one on the lower extremities) as fair, and three (two on the upper extremities and one on the lower extremities) as poor. Of the melasma cases, two were evaluated as excellent, five as good, two as fair, and one as poor. In the cases of postinflammatory hyperpigmentation, 10 (five on the face, two on the trunk, one on the upper extremities, and two on the lower extremities) were evaluated as excellent, 14 (six on the face, three on the trunk, four on the upper extremities, and one on the lower extremities) as good, three (one on the trunk, one on the upper extremities, and one on the lower extremities) as fair, and one (on the upper extremities) as poor. In the cases of nevus spilus, five (three on the face and two on the trunk) were evaluated as excellent, six (three on the face, one on the trunk, one on the upper extremities, and one on the lower extremities) as good, five (three on the face, one on the trunk, and one on the upper extremities) as fair, and two (one on the trunk and one on the lower extremities) as poor.

The success rate for cases of senile lentigines was 82.2 percent (95.1 percent, face, and 58.3 percent, upper extremities). The success rates for cases of melasma, postinflammatory hyperpigmentation, and nevus spilus were 70.0, 85.7, and 61.1 percent, respectively. Significant differences were not seen among the four diagnoses (H value = 2.67; $\chi^2(0.95) = 7.81$). However, when the lesions were classified according to location, a significant difference did exist (H value = 12.44; $\chi^2(0.95) = 7.81$). The success rates for the face, trunk, upper extremities, and lower extremities were 90.1, 71.4, 60.1, and 50.0 percent, respectively. The total success rate for the 146 cases was approximately 80 percent.

CASE REPORTS

Case 1

A 54-year-old woman with a senile lentigo on her left cheek underwent combined topical applications of 0.1% atRA gel and HQ-LA ointment without pretreatment (Fig. 1, *above, left*). The initial reaction (erythema and scaling) was appropriate (Fig. 1, *above, right*) and, at 2 weeks, the hyperpigmentation had disappeared completely, despite the severe ery-

FIG. 1. Case 1. A 54-year-old woman with a senile lentigo on the left cheek. (*Above, left*) Before treatment, (*above, right*) after 1 week, (*center, left*) after 2 weeks, (*center, right*) after 4 weeks, and (*below*) after 8 weeks of treatment.

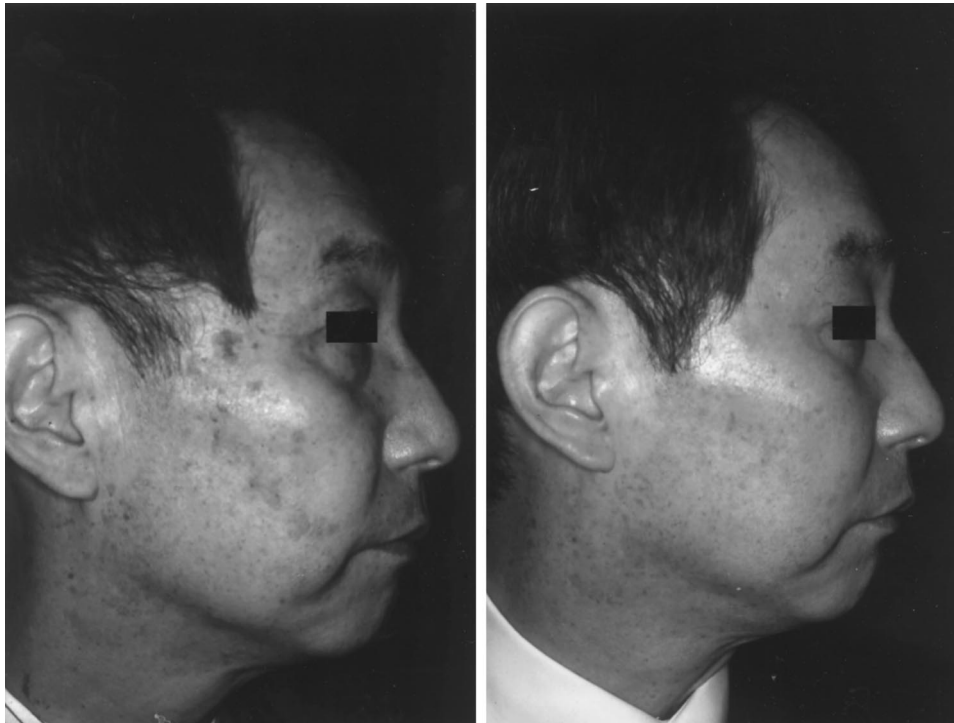


FIG. 2. Case 2. A 60-year-old man with senile lentigines on the face. Lateral views before treatment (*left*) and after 20 weeks of treatment (*right*).

thema and formation of a thin crust on the treated region (Fig. 1, *center, left*). AtRA gel and HQ-LA ointment were discontinued, and topical application of corticosteroid and HQ-AA was started. Corticosteroid ointment was applied for 2 weeks (Fig. 1, *center, right*). Four weeks after the discontinuation of the corticosteroid, the erythema disappeared completely (Fig. 1, *below*). HQ-AA ointment was applied throughout healing for 6 weeks and the final relative melanin value after 8 weeks of treatment was 4.3. The result was evaluated as excellent. Although the extent of erythema seen at 2 weeks was nearly the most severe among the cases we treated, the time course of the clinical changes in this patient was typical for the treatment. The relative melanin and hemoglobin values before treatment were 166.7 and 46.0, respectively. The relative hemoglobin value is generally positive in hyperpigmented lesions. During the bleaching step, the relative melanin value was considerably reduced, but the relative hemoglobin value increased as inflammation progressed. During healing, the relative hemoglobin value gradually decreased, but the improvement in the relative melanin value was maintained. The relative hemoglobin value was then reduced to below the level before treatment. The final relative melanin and hemoglobin values after 8 weeks of treatment were 4.3 and 18.8, respectively.

Case 2

A 60-year-old man with multiple senile lentigines on both cheeks underwent combined topical applications of 0.1% atRA gel and HQ-LA ointment without pretreatment (Fig. 2, *left*). Appropriate reactions were seen during the first and second week, and the healing step was started at 2 weeks. The hyperpigmentation and erythema had almost disappeared by the eighth week. Occasional application of atRA and HQ-LA ointment was done after treatment for maintenance (Fig. 2,

right). The relative melanin value of a pigmented spot before treatment was 52.3, and the final value after 8 weeks of treatment was -4.0 . The result was evaluated as excellent.

Case 3

A 23-year-old woman who had suffered superficial abrasive wounds on her face in a traffic accident 1 year before her first clinical visit showed postinflammatory hyperpigmentation at the sites of the wounds (Fig. 3, *left*). Topical applications of 0.1% atRA gel and HQ-LA ointment were started without pretreatment. On day 5, scaling was seen; thereafter, hyperpigmentation was reduced significantly. At 3 weeks, the healing step was started, and the erythema was almost eliminated at 8 weeks (Fig. 3, *right*). Relative melanin values before and after treatment were 41.4 and 6.1, respectively. The evaluation of this case was good.

Case 4

A 16-year-old woman with congenital nevus spilus on the left cheek underwent combined topical applications of 0.1% atRA gel and HQ-LA ointment without pretreatment (Fig. 4, *above, left*). The initial reaction (erythema and scaling) was appropriate, and the thin crusts came off during the second to third weeks (Fig. 4, *above, right*). The bleaching step lasted for 4 weeks; it was followed by a healing step of 4 weeks. The relative melanin value before treatment was 41.7; at 8 weeks, it was -3.5 (Fig. 4, *below, left*). Although HQ-LA ointment was continually applied after the treatment for maintenance, signs of recurrence were detected 6 weeks later. Therefore, atRA and HQ-LA ointment were applied once daily; this maintenance continued to work well, 10 months later (Fig. 4, *below, right*). The result was evaluated as excellent.

Case 5

A 61-year-old woman with nevus spilus on the left cheek who had undergone cryotherapy with dry ice four times and dermabrasion two times with no improvement underwent combined topical applications of 0.1% atRA gel and HQ-LA ointment without pretreatment (Fig. 5, *left*). The initial reactions (erythema and scaling) were appropriate, and the pigmentation was reduced significantly. Because the erythema gradually reduced during bleaching, the bleaching step was continued for 8 weeks, and no healing step was required. The relative melanin values before and after treatment were 72.3 and -3.6, respectively. The result was evaluated as excellent. Although the HQ-LA ointment was continually applied after treatment for maintenance, signs of recurrence were observed 1 month after the cessation of atRA. AtRA and HQ-LA ointment were used continually for maintenance, and the pigmentation was controlled well 18 months later (Fig. 5, *right*).

DISCUSSION

Characteristics of the Present Protocol

AtRA and hydroquinone play essential roles in our treatment for bleaching, and lactic acid and ascorbic acid are used supplementally. Although ascorbic acid also has a depigmenting effect and fewer adverse effects than hydroquinone, its depigmenting ability is far less than that of hydroquinone.¹⁵ It is clear that the same results cannot be obtained from the single use

of either atRA⁵ or hydroquinone.¹⁶ Although hydroquinone was used also in the healing step, we did not expect it to further improve pigmentation but to prevent postinflammatory hyperpigmentation and the recurrence of pigmentation, thus maintaining the level of improvement obtained in the bleaching step.

On the basis of our preliminary trials with several concentrations of atRA in several vehicles and the concomitant use of corticosteroid ointment with atRA, we think that the critical points of this protocol are (1) to use a high concentration of atRA aqueous gel and (2) not to use corticosteroids concomitantly with atRA. Various kinds of atRA gels with higher concentrations than those commercially available were originally prepared. A cream-based, 0.01% to 0.1% concentration of atRA (0.01% to 0.1% Retin-A) has been widely used, and the concentration of atRA in aqueous gel-based products is usually lower because of the higher permeability of the vehicle. We prepared a 0.1% to 0.4% concentration of atRA using aqueous gel as a vehicle because of its higher permeability and economic benefits. We assume that 0.1% atRA aqueous gel corresponds to 0.3% to 0.4% atRA cream or hydrophilic

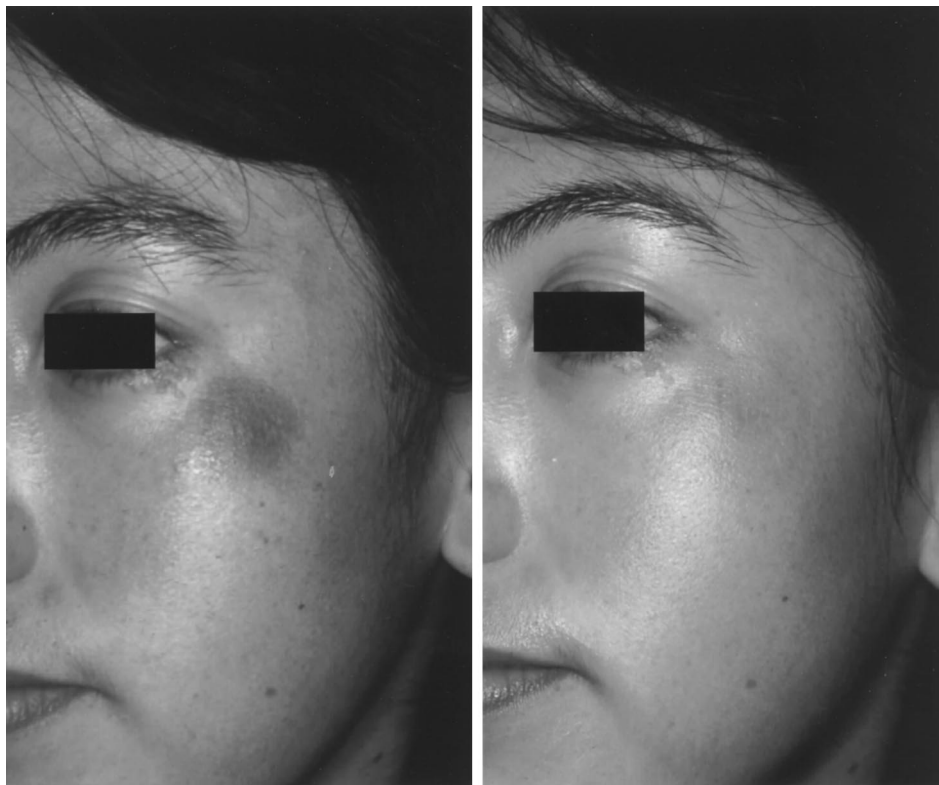


FIG. 3. Case 3. A 23-year-old woman with postinflammatory hyperpigmentation on the cheek. Before treatment (*left*) and after 8 weeks of treatment (*right*).

ointment in terms of the efficiency of drug delivery. Because atRA is pharmacologically unstable, its concentration in our vehicle is spontaneously reduced to 90 percent in 1 month (data not shown), even when stored in a refrigerator. Thus, it is necessary for new atRA gel to be prepared at least once a month.

Effectiveness on Skin Hyperpigmentation

The present results demonstrated that the effectiveness of the treatment varies according to the diagnosis and location of the lesions. Although statistical significance was not detected, the success rates for senile lentigines

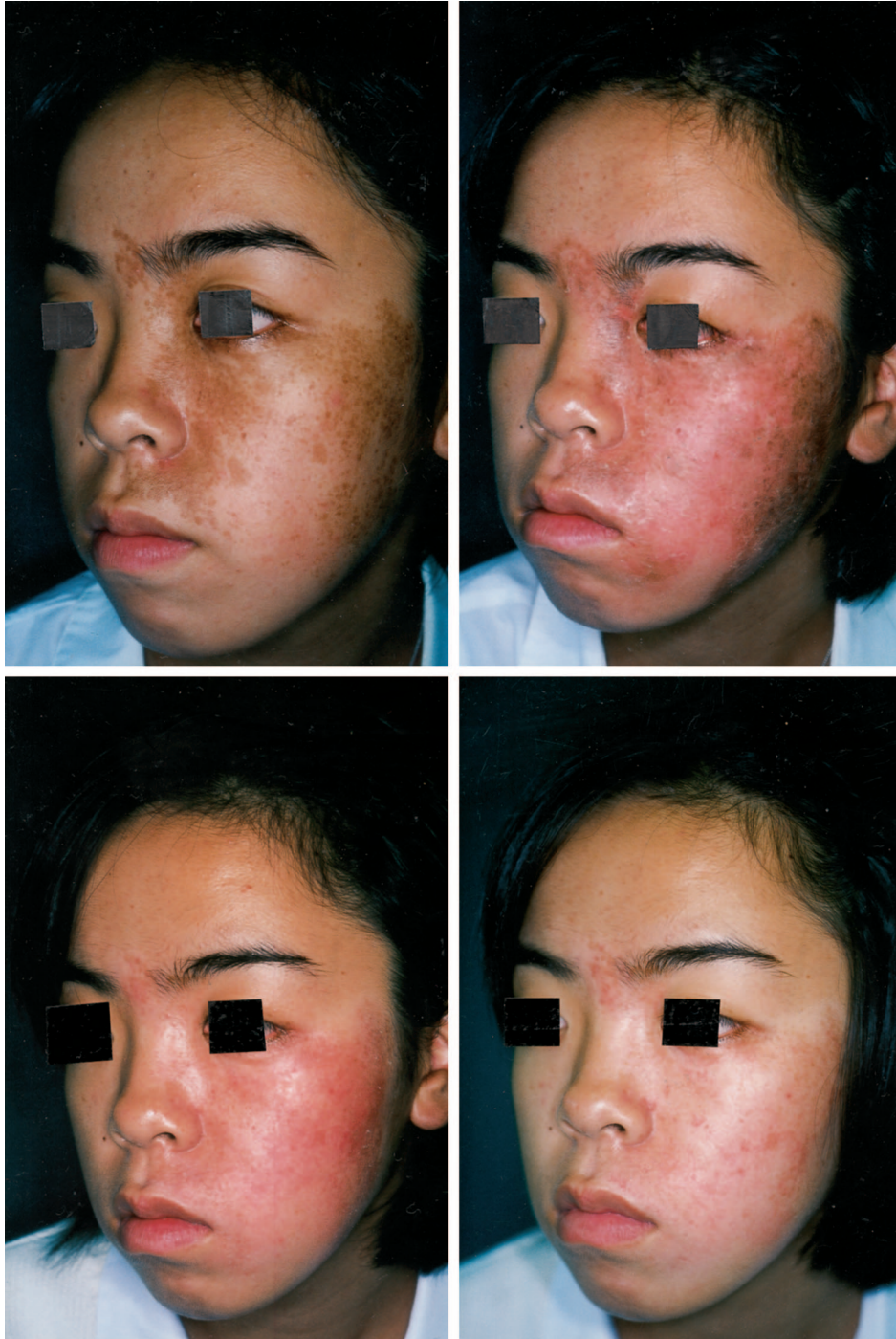


FIG. 4. Case 4. A 16-year-old girl with congenital nevus spilus on the left cheek. (Above, left) Before treatment, (above, right) after 3 weeks, (below, left) after 8 weeks, and (below, right) after 12 months of treatment.

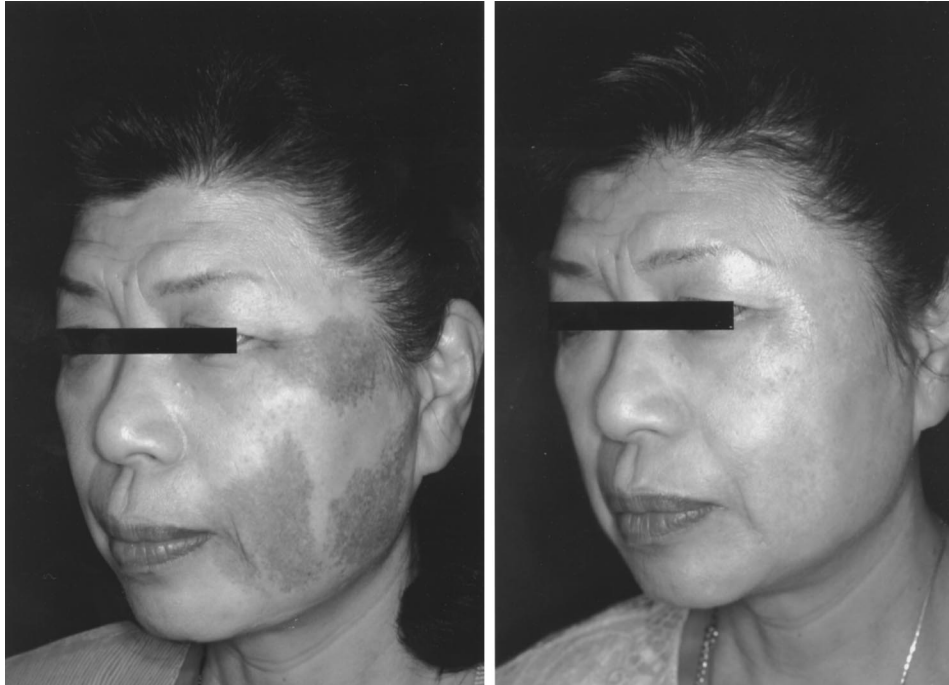

FIG. 5. Case 5. A 61-year-old woman with nevus spilus on the left cheek. Before treatment (*left*) and after 8 months of treatment (*right*).

and postinflammatory hyperpigmentation were very high, especially for lesions on the face. The success rate for nevus spilus was approximately 60 percent. However, neither laser therapies nor any other therapies combined with hydroquinone can treat nevus spilus very well, and the recurrence of pigmentation with these other treatments is also very common, suggesting that our bleaching protocol has potential as a therapy for nevus spilus.

The location of the skin lesions is also quite important in this therapy. The success rate for the face was more than 90 percent, and that for the trunk and upper extremities was 71.4 and 60.1 percent, respectively. Although the number of cases was small, the success rate for the lower extremities was only 50 percent. Statistical significance existed according to the locations of the lesions. The skin reactions to atRA are milder and slower on the trunk and extremities, especially on the lower extremities, than on the face. Differences in the permeability and vascularity of the skin, associated with the penetration and resorption of the agent and wound healing, are suspected to be the main reasons for the differences in the skin reactions. Therefore, higher concentrations of atRA were used in this protocol for the trunk and extremities: 0.2 percent atRA gel for the

trunk and upper extremities and 0.4 percent for the lower extremities. This led to much better clinical results than using 0.1 percent atRA gel.

Mechanisms of Action of atRA and Hydroquinone

The mechanisms by which atRA and hydroquinone act in the combined protocols,^{6,7} must still be elucidated. Although a number of studies have been performed to determine the effects of atRA on skin in vivo or on keratinocytes and other cells in the skin in vitro, contradictory results exist. The reasons for this remain unknown.^{3,17,18} Although reportedly even the topical application of atRA alone has a clinically depigmenting effect,^{5,19,20} the suppressive effects of atRA on melanocyte growth and melanogenesis have not been established in vitro.²¹ AtRA promotes the proliferation of keratinocytes in vivo, and hyperplasia of the epidermis is a characteristic change after the topical application of atRA.³ However, the promotion of keratinocyte growth is variable in vitro.¹⁸ It was reported that atRA can promote collagenesis and wound healing.^{2,22,23} On the other hand, skin becomes atrophic after the application of corticosteroids,^{24,25} and corticosteroids suppress collagenesis and wound healing.²⁶ Thus,

corticosteroids seem to be antagonistic to retinoids in some respects.^{2,24,25,27}

Corticosteroids have a depigmenting effect with single use,²⁸ and this is one of the reasons why Kligman and Willis⁶ used it in their regimen.⁶ However, on the basis of our preliminary clinical results and the differences between the results of the present report and those of other conventional reports in which atRA and corticosteroids were concomitantly used, we think that corticosteroids suppress the beneficial effects of atRA in the depigmenting treatment and should be minimally used in bleaching therapies with atRA. Also, in our experience, peeling procedures, such as the use of the carbon dioxide laser followed by topical hydroquinone treatment, do not create the same results, suggesting that the scaling or peeling effect is not the primary role of atRA in this treatment. Taken together, we speculate that the strong promotion of keratinocyte proliferation and wound healing is, most likely, the role of atRA in this depigmenting protocol. The promotion of permeability induced by repeated scaling and mucinous accumulation in the extracellular spaces may be a supplemental benefit of atRA in this treatment.²⁹

Side Effects

Adverse effects on the skin, such as irritation and erythema, occurred at a higher rate in this protocol than in conventional ones because of the high concentrations of atRA used.¹⁴ Indeed, 10 to 15 percent of the patients did not complete the treatment, although accurate assessment of the number of dropouts was difficult because some patients did not revisit the hospital for unknown reasons. Although it was reported that high concentrations of atRA accentuate irritation without a corresponding gain in effectiveness,^{2,30} our protocol with higher concentrations of atRA aqueous gel led to much better objective and clinical results and subjective satisfaction than the lower concentrations. These differences may be partly derived from the racial differences in the subjects.

Continuous application of atRA leads to tolerance in the treated skin.³¹ After a few weeks of treatment, the side effects (such as erythema and irritation) decrease, even during the bleaching step. Indeed, it was not necessary to conduct the healing step in some patients, such as case 5. Also, we have some patients who use 0.4 percent atRA gel on the face for main-

tenance, without any adverse skin effects. Although the mechanism by which tolerance is obtained and whether the beneficial effects of atRA are lost have not been established, the increased tolerance is the reason why we usually need to use the higher concentration of atRA gel in the second treatment.

Another possible side effect is postinflammatory hyperpigmentation induced by the skin inflammation of the bleaching step. During the healing step, erythema is gradually reduced, but postinflammatory hyperpigmentation occurred in some patients. In most of these patients, the hyperpigmentation gradually disappeared in a couple of months. Otherwise, it can be treated by our treatment protocol. The skin color of Oriental patients may be one of the factors causing postinflammatory hyperpigmentation.

Recurrence

In patients with senile lentigines or melasma who were followed-up for more than 6 months, recurrence of the lesion was occasionally observed, but the number of such cases was small. It rarely occurred in patients with postinflammatory hyperpigmentation, but a total of 80 to 90 percent of the cases of nevus spilus exhibited some signs of recurrence a couple of months after treatment ceased. However, recurring pigmentation was usually reduced or eliminated by the second treatment in cases in which the first treatment was effective. Therefore, continual treatment with atRA or hydroquinone is recommended in patients with nevus spilus, even when the result of the first treatment is excellent. Only in pregnant patients with nevus spilus could it be a problem to continue treatment with atRA, which is a possible teratogen.³²

Indication of the Treatment and Application to Combination Therapies

The present protocol can be applied to almost any kind of skin lesion with hyperpigmentation, preferably when the intensity of pigmentation is high, for example, when the relative melanin value is more than 30. Taking into consideration the fact that the reactive inflammation accompanying the bleaching step may induce postinflammatory hyperpigmentation during the healing step, any other mild treatment could be recommended for lesions with weak pigmentation, for example, when the relative melanin value is less than 15.

It should be noted that our bleaching protocol is not very effective for lesions with hyperkeratosis. In such cases, other treatments, such as liquid nitrogen and carbon dioxide laser, should be applied before the bleaching step. Possible side effects during the bleaching step should be explained well, and the firm intention of the patients to undergo aggressive treatment should be confirmed before starting the bleaching step, as with any other surgery or chemical peel. Finally, it is emphasized that repeated treatments with this protocol can remarkably improve photoaged skin, not only in terms of skin color, but also in skin texture and elasticity; it eliminates surface roughness and fine wrinkles.

CONCLUSIONS

The authors propose a strong bleaching protocol in which atRA aqueous gels were used at high concentrations and corticosteroids were used minimally. Although reactive adverse effects may be more severe, the present protocol improves hyperpigmentation, with a higher success rate and a shorter treatment period than conventional protocols. It is also the first one with effectiveness in treating nevus spilus. The success rates varied according to diagnosis and location of skin lesions. High success rates were obtained for cases of senile lentiginos and postinflammatory hyperpigmentation and lesions on the face. The present protocol can be applied to almost any kind of skin lesion with hyperpigmentation, preferably when the intensity of pigmentation is very high.

Kotaro Yoshimura, M.D.
 Department of Plastic, Reconstructive, and
 Aesthetic Surgery
 University of Tokyo
 7-3-1, Hongo, Bunkyo-Ku
 Tokyo 113-8655, Japan
 yoshimura-pla@h.u-tokyo.ac.jp

ACKNOWLEDGMENTS

The authors thank Yuka Kuwahara and Takako Kato for their assistance in spectrophotometric measurements.

REFERENCES

1. Apfelberg, D. B. Ultrapulse carbon dioxide laser with CPG scanner for full-face resurfacing for rhytids, photoaging, and acne scars. *Plast. Reconstr. Surg.* 99: 1817, 1997.

2. Kligman, L. H., Duo, C. H., and Kligman, A. M. Topical retinoic acid enhances the repair of ultraviolet damaged dermal connective tissue. *Connect. Tissue Res.* 12: 139, 1984.
3. Kligman, A. M., Grove, G. L., Hirose, R., and Leyden, J. J. Topical tretinoin for photoaged skin. *J. Am. Acad. Dermatol.* 15: 836, 1986.
4. Leyden, J. J. Treatment of photodamaged skin with topical tretinoin: An update. *Plast. Reconstr. Surg.* 102: 1667, 1998.
5. Rafal, E. S., Griffiths, C. E. M., Ditre, C. M., et al. Topical tretinoin (retinoic acid) treatment for liver spots associated with photodamage. *N. Engl. J. Med.* 326: 368, 1992.
6. Kligman, A. M., and Willis, I. A new formula for depigmenting human skin. *Arch. Dermatol.* 111: 40, 1975.
7. Gano, S. E., and Garcia, R. L. Topical tretinoin, hydroquinone, and betamethasone valerate in the therapy of melasma. *Cutis* 23: 239, 1979.
8. Pathak, M. A., Fitzpatrick, T. B., and Kraus, E. W. Usefulness of retinoic acid in the treatment of melasma. *J. Am. Acad. Dermatol.* 15: 894, 1986.
9. Nordlund, J. J. Postinflammatory hyperpigmentation. *Dermatol. Clin.* 6: 185, 1988.
10. Grimes, P. E. Melasma. Etiologic and therapeutic considerations. *Arch. Dermatol.* 131: 1453, 1995.
11. Alster, T. S. Laser Treatment of Pigmented Lesions. In *Manual of Cutaneous Laser Techniques*. Philadelphia: Lippincott-Raven, 1997. Pp. 45-62.
12. Taylor, C. R., and Anderson, R. R. Treatment of benign pigmented epidermal lesions by Q-switched ruby laser. *Int. J. Dermatol.* 32: 908, 1993.
13. Yoshimura, K., Harii, K., Masuda, Y., et al. Usefulness of a narrow-band reflectance spectrophotometer in evaluating effects of depigmenting treatment. *Aesthetic Plast. Surg.* (in press).
14. Yoshimura, K., Harii, K., Aoyama, T., et al. A new bleaching protocol for hyperpigmented skin lesions with a high concentration of all-trans retinoic acid aqueous gel. *Aesthetic Plast. Surg.* 23: 285, 1999.
15. Maeda, K., and Fukuda, M. In vitro effectiveness of several whitening cosmetic components in human melanocytes. *J. Soc. Cosmet. Chem.* 42: 361, 1991.
16. Kenneth, A. A., and Fitzpatrick, T. B. Topical use of hydroquinone as a depigmenting agent. *J.A.M.A.* 194: 117, 1965.
17. Eichner, R. Epidermal effects of retinoids: In vitro studies. *J. Am. Acad. Dermatol.* 15: 789, 1986.
18. Fisher, G. J., and Voorhees, J. J. Molecular mechanism of retinoid actions in skin. *FASEB J.* 10: 1002, 1996.
19. Griffiths, C. E. M., Finkel, L. T., Ditre, C. M., et al. Topical tretinoin (retinoic acid) improves melasma: A vehicle-controlled, clinical trial. *Br. J. Dermatol.* 129: 415, 1993.
20. Griffiths, C. E. M., Goldfarb, M. T., Finkel, L. J., et al. Topical tretinoin (retinoic acid) treatment of hyperpigmented lesions associated with photoaging in Chinese and Japanese patients: A vehicle-controlled trial. *J. Am. Acad. Dermatol.* 30: 76, 1994.
21. Ortonne, J. P. Retinoic acid and pigment cells: A review of in-vitro and in-vivo studies. *Br. J. Dermatol.* 127 (Suppl. 41): 43, 1992.
22. Schwartz, E., Cruickshank, F. A., Mezick, J. A., and Kligman, A. M. Topical tretinoin (retinoic acid) treatment of hyperpigmented lesions associated with photoaging in Chinese and Japanese patients: A vehicle-controlled trial. *J. Am. Acad. Dermatol.* 30: 76, 1994.

- man, L. H. Topical all-trans retinoic acid stimulates collagen synthesis in vivo. *J. Invest. Dermatol.* 96: 975, 1991.
23. Kang, S., Fisher, G. J., and Voorhees, J. J. Photoaging and topical tretinoin: Therapy, pathogenesis, and prevention. *Arch. Dermatol.* 133: 1280, 1997.
24. McMichael, A. J., Griffiths, C. E. M., Talwar, H. S., et al. Concurrent application of tretinoin (retinoic acid) partially protects against corticosteroid-induced epidermal atrophy. *Br. J. Dermatol.* 135: 60, 1996.
25. Lesnik, R. H., Mezick, J. A., Capetola, R. J., and Kligman, L. H. Topical all-trans retinoic acid prevents corticosteroid-induced skin atrophy without abrogating the antiinflammatory effect. *J. Am. Acad. Dermatol.* 21: 186, 1989.
26. Leyden, J. J., Thew, M., and Kligman, A. M. Steroid rosacea. *Arch. Dermatol.* 110: 619, 1974.
27. Ulland, A. E., Shearer, J. D., Coulter, C., and Caldwell, M. D. Altered wound healing arginine metabolism by corticosterone and retinoic acid. *J. Surg. Res.* 70: 84, 1997.
28. Arnold, J., Anthonioz, P., and Marchand, J. P. Depigmenting action of corticosteroids: Experimental study on guinea pigs. *Dermatologica* 151: 274, 1975.
29. Bhawan, J. Short- and long-term histologic effects of topical tretinoin on photodamaged skin. *Int. J. Dermatol.* 37: 286, 1998.
30. Griffiths, C. E. M., Kang, S., Ellis, C. N., et al. Two concentrations of topical tretinoin (retinoic acid) cause similar improvement of photoaging but different degrees of irritation. *Arch. Dermatol.* 131: 1037, 1995.
31. Helander, S. D. Treatment of photoaged skin: Efficacy, tolerability and costs of available agents. *Drugs Aging* 8: 12, 1996.
32. Nau, H. Embryotoxicity and teratogenicity of topical retinoic acid. *Skin Pharmacol.* 6 (Suppl. 1): 35, 1993.